

Endocrine Society DocMatter Community

How To Share Your Content

(Cases, Literature, Event Announcements, Basic Science, and more...)

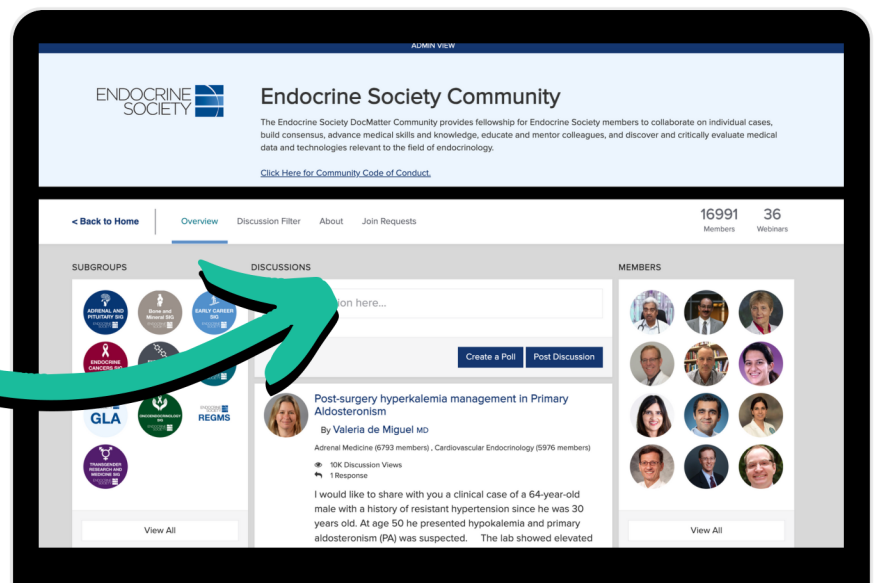



Step 1: Log In

Visit [DocMatter.com/Endo](https://www.docmatter.com/Endo) or Download the DocMatter App

Step 2: Draft Post

Click on the "Start discussion" box to draft your post



Step 3: Best Practices

- Posts should be applicable to more than a handful of members
- End with an open ended, controversial or thought-provoking question to encourage discussion

Learn more about the Community:

<https://www.endocrine.org/membership/docmatter-community>

Contact if you need assistance: SBonin@DocMatter.com

How To Share Your Content

(Cases, Literature, Event Announcements, Basic Science, and more...)

Example #1 of a Great Post Clinical Case



Uncontrolled Graves disease at 32/5 wks on high dose methimazole. Any thoughts on adding SSKI (40 mg) daily?

By [Redacted]

Thyroidology (8628 members)

👁 16K Discussion Views

👤 15 Responses

20 yo G2P0100 with Graves disease. She was seen in prior pregnancy last year-difficulty keeping appts but she had markedly elevated TT4 23 ug/dl (4.5-10.9) and TT3 3.26 ng/ml (0.6-1.8) on methimazole 20 bid- I added cholestyramine but she had trouble tolerating. She delivered at 36 wks w pre-eclampsia. No neonatal hyperthyroidism but tragically her baby died 3 wks later of sepsis.

She presented again to me late in pregnancy (end of 2nd trimester)-followed w another endo. Despite methimazole 30 mg bid (she swears she is taking it) her labs from 3/23 done by other endo: FT4 3.2 ng/dl (0.6-1.2), FT3 10.11 (pg/ml (2.5-3.90). TSI markedly elevated.

I have ordered TT4 and T3 today. Fetal US- no goiter, tachycardia and growth is normal.

She has a 100 gm thyroid w a bruit and clinically is hyperthyroid. Given the severity of her hyperthyroidism, I entertained adding SSKI. I could not find much in the literature. Momotani, et al. JCEM 75:738; 1992 used SSKI as sole therapy without any clear fetal effects (although these pts were not very hyperthyroid).

Do I:

Sit tight?

Increase methimazole?- I am very hesitant to do this

Try SSKI 40 mg as documented above.

Previously unable to tolerate cholestyramine.

Thanks for your thoughts.

Marc

How To Share Your Content

(Cases, Literature, Event Announcements, Basic Science, and more...)

Example #2 of a Great Post Event Announcement



Medullary thyroid cancer - evaluation/treatment?

By [Redacted]
Assistant Professor

👁 4,199 Discussion Views
↩ 4 Responses

A 45-year-old male was found to have palpable thyroid enlargement confirmed to be a 2.5 cm thyroid nodule on neck ultrasonography. There were no suspicious lateral neck lymph nodes. The nodule was solid, hypoechoic TR4 hence fine needle aspirate was done which resulted as suspicious for follicular neoplasm (Bethesda IV), following which molecular marker testing resulted as medullary thyroid cancer (MTC).

Questions:

1. What other evaluation is necessary: biochemical such as Calcitonin, Carcinoembryonic antigen (CEA), imaging?
2. Is central neck dissection performed in addition to thyroidectomy in all cases?
3. If patient had unilateral lateral neck lymph node positive for MTC, then in addition to total thyroidectomy + central neck dissection + left lateral neck dissection, would there be consideration for contralateral lateral neck dissection?

For those interested in further discussing this case, we will be covering this on an upcoming webinar about Medullary Thyroid Cancer. Registration/event details are located here: [Endocrine Society Registration Page](#)